

Clinical improvement after treatment with VEGF₁₆₅ in patients with severe chronic lower limb ischaemia

Andrei Anghel · Bogdan Mut-Vitcu · Lorand Savu ·
Catalin Marian · Edward Seclaman · Raluca Iman ·
Adriana-Maria Neghina · Stefan I. Dragulescu

Received: 20 October 2006 / Accepted: 30 April 2007
© Springer Science+Business Media B.V. 2007

Abstract The present study focuses on the application of a therapeutic strategy in patients with chronic severe lower limb ischaemia using a plasmid vector encoding the vascular endothelial growth factor (phVEGF₁₆₅). It has been shown that VEGF promotes neo-vascularization and blood vessel network formation and thus might have the ability to improve blood-flow at the level of the affected limbs. However, little information is available regarding the necessary level of expression of *VEGF* and its possible related adverse effects. We have subcloned *VEGF*₁₆₅ isoform into pCMV-Script expression vector (Stratagene) under the control of the CMV promoter. Three patients with chronic ischaemia of the lower limb, considered as not suitable for surgical re-vascularization, received intramuscular injection with 0.5 ml saline solution containing 10¹¹ copies of *VEGF*₁₆₅ plasmid. The clinical evolution has been monitored by angiography and estimated by walking time on the rolling carpet (Gardner protocol). Two months after therapy, all three patients showed complete relief of rest pain, improvement of ischaemic ulcer lesions and increased walking distance on the rolling carpet most probably due to appearance of newly formed collateral vessels.

Keywords Gene therapy · Lower limb ischaemia · Neo-vascularization · Vascular endothelial growth factor

Abbreviations

CMV	cytomegalovirus
PCR	Polymerase chain reaction
RT-PCR	Real time PCR
FLK 1	fetal liver kinase 1 (VEGF receptor 2)
FLT 1	Fms-like tyrosine kinase 1 (VEGF receptor 1)
KDR	kinase insert domain receptor (a type III receptor tyrosine kinase)
VEGF	Vascular endothelial growth factor
VEGF ₁₆₅	VEGF isoform with 165 aminoacids

Introduction

Cardiovascular disease represents a major cause of morbidity and mortality worldwide with atherosclerosis being one of the main pathological mechanism involved. Previous studies have shown a strong relationship between atherosclerosis promoting factors (high blood pressure, diabetes mellitus, smoking, hyperlipidemia, sedentariness) and the development of the peripheral ischaemic disease (Brown et al. 1972; Helmlinger et al. 2000). This condition affects mainly the arteries of the lower limb leading to decreased blood flow with subsequent ischaemic lesions. Severe lower limb ischaemia accounts for 70% of the 150 million lower limb amputations (Eskelinen et al. 2004).

Conventional treatment of lower limb ischaemia has two main components: conservative and interventional/surgical therapy. The conservative approach includes modification

A. Anghel (✉) · C. Marian · E. Seclaman ·
A.-M. Neghina
Department of Biochemistry, “Victor Babes” University of
Medicine and Pharmacy Timisoara, 2nd Eftimie Murgu Square,
Timisoara, Romania
e-mail: biochim@umft.ro

B. Mut-Vitcu · R. Iman · S. I. Dragulescu
Timisoara Institute of Cardiovascular Medicine, Timisoara,
Romania

L. Savu
GeneticLab SRL, Bucharest, Romania

of the risk factors (smoking cessation, control of glycaemia and blood pressure, decrease of lipid levels) associated with anti-platelet therapy (aspirin). Ischaemic rest pain is alleviated with pain medication ad libitum associated with correction of any underlying systemic cause of low blood flow (such as cardiac failure). Patients not responding to conservative therapy are candidates for surgical treatment, revascularization (angioplasty, stent placement and bypass surgery with autologous veins or prosthetic conduits) and amputation.

Gene therapy with vascularization promoting factors (VEGF, angiopoietins, hepatocyte growth factor) has been established as a potential strategy for inducing re-vascularization in patients with severe lower limb ischaemia (Isner et al. 1996; Isner et al. 1998; Thurston et al. 2000; Rajagopalan et al. 2001; Shyu et al. 2003; Gerritsen 2005).

In contrast to other polypeptide mitogens, VEGF (also called vascular promoting factor) is primarily active on vascular endothelial cells. Analysis of *VEGF* transcripts by PCR, DNA cloning (Tischer et al. 1991) or RT-PCR (Poltorak et al. 1997) identified 5 isoforms with 121, 141, 145, 165 and 189 amino acids. VEGF controls blood vessel formation and permeability by interacting with 2 endothelial tyrosine kinase receptors FLT 1 and KDR/FLK 1. VEGF₁₆₅ seems to be the predominant form and has a specific receptor (VEGF₁₆₅R) identical to neuropilin-1 (Bacic et al. 1995; Soker et al. 1998).

VEGF expression is regulated by the level of glycaemia and oxygen, both hypoglycaemia and hypoxia being strong inducers of VEGF synthesis (Helmlinger et al. 2000; Dantz et al. 2002). Reduced tissue level of nutrients and oxygen are common features of peripheral ischaemic disease, thus providing a rationale for using VEGF in the treatment of chronic lower limb ischaemia.

Nevertheless, *VEGF* therapy for lower limb ischaemia is still controversial and very few data are known about the level of expression necessary in order to achieve a therapeutic effect and, even more, about the related side effects. Recent reports indicated that transgenic (Thurston et al. 1999) or adenoviral (Thurston et al. 2000) over-expression of *VEGF* resulted in formation of leaky vessels in laboratory animals (Isner et al. 1998; Blau and Banfi 2001) and that plasmid-based intramuscular *VEGF* gene transfer led to transient oedema in human subjects (Baumgartner et al. 2000). Combinations of VEGF with other growth factors (such as with angiopoietin-1, hepatocyte growth factor) have been tested as alternative strategies to promote new vessel growth and limit the oedema associated with VEGF (Gerritsen 2005).

The present study evaluates the clinical outcome (rest pain, claudication, evolution of ischaemic ulcerative lesions, walking distance on rolling carpet as assessed by

Gardner protocol) and angiographically assesses the formation of new blood vessels after *VEGF*₁₆₅ gene therapy in patients with severe chronic lower limb ischaemia.

Methods

Study design

We designed a single blind study aiming at analysing the possible effect of VEGF₁₆₅ muscle overexpression on the clinical evolution of the patients diagnosed with lower limb severe chronic ischaemia unresponsive to classical treatment.

The study protocol was approved by the Ethics Committee of the “Victor Babes” University of Medicine and Pharmacy from Timisoara, Romania.

Patients

Patients (35–53 years old) with severe lower limb ischaemia admitted at the Institute for Cardiovascular Disease from Timisoara, Romania were screened for this study based on specific clinical and laboratory investigations. We focused our study on lower limb ischaemia patients for whom the amputation was the only therapeutic alternative left.

Inclusion criteria

- (1) Evidence of severe lower limb ischaemia, including rest pain (not responding to analgesic therapy) and skin ulcerous lesions (that had not healed after at least 1 month of conventional therapy).
- (2) Angiography showing obliteration of limb arteries.
- (3) Unsuitability for surgical or percutaneous revascularization based on usual practice standards.

Exclusion criteria

- (1) Women of fertile age undergoing treatment with antiplatelet or thrombolytic medication started less than 1 month prior to the onset of the procedure
- (2) Patients under therapy with prostaglandins (less than 3 months prior to the onset of the procedure) and immunosuppressants.
- (3) History of osteomyelitis, coronary diseases, stroke, renal insufficiency, hepatitis, diabetes and proliferative diabetic retinopathy, malignancy.
- (4) Admission to a recuperative care program based on physical therapy.

All patients have undertaken screening tests (blood, urine, stool exam, chest X-ray, abdominal ultrasonography,

ophthalmologic examination) prior to admission into the program.

Patients gave their written informed consent for being taken into the study and subjected to the therapeutic procedure.

Patient monitorisation after procedure

We designed a two step follow-up protocol meant to accurately monitor the changes in the health status of our patients and to allow a prompt response in case of a life threatening situation. The early phase spanned the first three days post-therapy and consisted of a close clinical monitoring of general health status, evolution of the ischaemia symptoms and the appearance of possible side-effects of therapy (oedema of the cured lower limb, fever, increased levels of acute phase reactants). The second step of monitorisation phase scheduled clinical tests (walking test, ankle-brachial index), control angiography, investigation of acute phase reactant levels, ophthalmologic examination, routine hematology and blood chemistry, and urinalysis at two, four and eight weeks post procedure.

VEGF₁₆₅ vector construction and multiplication

Human Lung cDNA from Clontech was used for multiplication and insertion of the VEGF₁₆₅ gene (GenBank accession no. AB021221) into the pCVM-Script mammalian expression vector (Stratagene) under the control of the cytomegalovirus promoter/enhancer. The VEGF₁₆₅ specific cDNA was amplified by PCR using the following primers: 5'-ttgccgaattcatgaacttctgctgtcttggt-3' and 5'-tttggccctcgagtcaccgctcgcttgctcac-3'. The primers contain the restriction sites for EcoRI and XhoI enzymes, subsequently used for insertion of the VEGF₁₆₅ cDNA into the expression vector.

PCR reaction was carried out in a final volume of 20 µl containing 50 ng genomic DNA, 1x HotStar Taq DNA Polymerase buffer with 1.5 mM MgCl₂ (Qiagen), 4 pmol of each primer, 1UI HotStar Taq DNA Polymerase (Quiagen) and 2.5 mM dNTPs. PCR amplification conditions were as follows: initial denaturation and HotStar Taq Polymerase activation at 95°C for 15 min; 35 cycles of 30 s at 95°C, 30 s at 62°C with 45 s extension at 72°C; final extension of 7 min at 72°C. In order to verify the nucleotidic sequence of the obtained VEGF₁₆₅ specific cDNA, the amplicons were subsequently bidirectionally sequenced using the BigDye Terminator sequencing kit (Applied Biosystems) according to the manufacturer's instructions on an ABI Prism 310 capillary electrophoresis device (Applied Biosystems). The obtained sequence was compared with the GenBank reference sequence with the

aid of the Sequencing Analysis v3.1 (Applied Biosystems) software.

The VEGF₁₆₅ cDNA was cut with EcoRI and XhoI (Promega) followed by ligation using the T4 DNA Ligase System (Promega) purified from agarose gel with MiniElute Gel Extraction Kit (Qiagen) and introduced into pCMV-Script linearised vector using the T4 DNA Ligase System (Promega).

For transformation and selection of clones we used XL1-Blue Supercompetent Cells (Stratagene) cultured at 37°C on LB Agar plates containing kanamycin. In order to verify the presence of the insert, the selected colonies were tested by PCR and sequenced as described above.

The colonies containing the correct insert were then cultured overnight at 37°C on LB Broth liquid medium. Vector purification was performed using the GenElute HP Plasmid Maxiprep Kit (Sigma) following the manufacturer's protocol; purity and quantity of the obtained vector were measured by UV spectrometry. The measured 260/280 ratio showed no protein contamination, being constantly over 1.9, and the quantity obtained was around 1.3×10^{13} copies of vector.

VEGF₁₆₅ vector conditioning and administration

The whole quantity of purified vector was brought to 50 ml in sterile Falcon tubes with 0.9% NaCl sterile perfusion solution. The obtained solution was then subjected to a standard sterility verification protocol, by cultivating 1 ml in bullion medium for 5 days followed by subsequent cultivation on aerobe and anaerobe specific media, respectively. No bacterial growth was observed in any case.

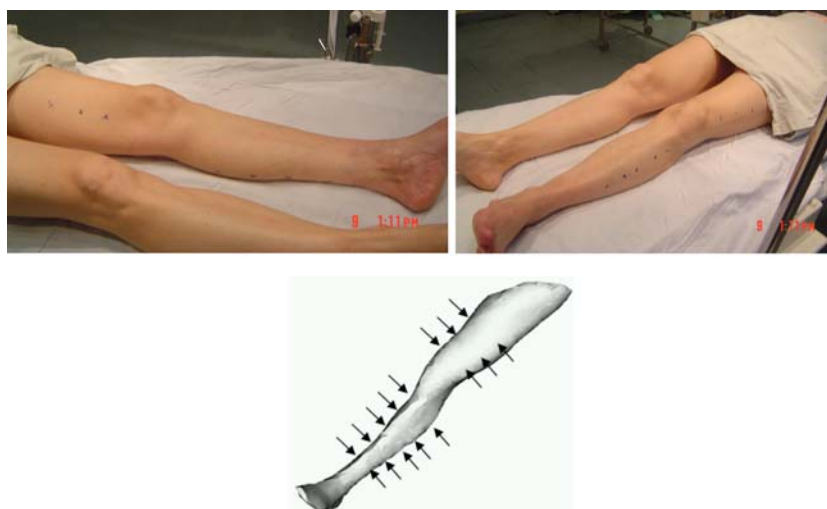
Administration was performed by intramuscular injection of a total of 3 mls saline solution containing 10^{11} /ml copies of vector into the thigh (6 injections) and calf muscles (10 injections) (at 3–4 cm intervals), on a trajectory with potential angiogenic benefit, as judged by the most recent angiography of the ischaemic leg (Fig. 1).

Results

Among the 39 patients screened we found 3 patients eligible for the study; the remaining 36 patients met the criteria for interventional revascularization.

The study group included 1 male and 2 females with ages ranging from 35 to 53 years old; the clinical data of the patients (prior and post therapeutic intervention) are shown in Table 1.

Following gene therapy all patients showed an initial temporary increase of the acute phase reactant levels (C-

Fig. 1 The injection sites**Table 1** Clinical and angiographic findings before and after VEGF gene therapy

Clinical history and findings before gene therapy						Outcomes after gene therapy (2 months)	
No.	Gender	Age (years)	Diagnosis	Signs/symptoms	Angiographic findings	Signs/symptoms	Angiographic findings
1	Female	46	Thromboangiitis obliterans; critical ischaemia of the left foot	Claudication at 200 m, resting pain, toe gangrene (digits IV–V)	Complete occlusion of the superficial femoral artery, without blood supply in the popliteal artery through collateral vessels, perfusion only in the distal half of the peroneal artery	Claudication at 350 m, resting pain decreased, gangrene area reduced (digit V)	No detectable changes
2	Female	35	Chronic obliterative arteriopathy of the right lower limb, stage II B; critical ischaemia of the right foot	Claudication at 150 m, resting pain, toe gangrene (digit I)	Occlusion in the proximal region of the right anterior tibial artery, occlusion in the middle region of the posterior tibial artery	Claudication at 450 m, resting pain decreased, gangrene area reduced	No detectable changes
3	Male	53	Chronic obliterative arteriopathy of the left lower limb, stage II B	Claudication at 50 m, resting pain	Chronic bilateral occlusion of the superficial femoral artery, occlusion of the left popliteal artery and left calf arteries.	Claudication at 200 m, resting pain decreased	Visible new formed collateral vessels at the level of the calf

reactive protein) with peaks within the first 6–48 h, reaction which was considered normal after intramuscular administration of the plasmid vectors (Fig. 2). No local oedema was observed in any of the patients at the sites of injection. One patient (number 3 in Table 1) developed a short episode of fever (38.6°C) at 2 h after injection, but this was completely controlled by administration of 100 mg hydrocortisone hemisuccinate.

Erythrocyte sedimentation rate decreased significantly in patient 1 with a minimum at 48 h. In the case of the other 2 patients (and in contrast with the C-reactive protein levels) we observed minimal increases of the sedimentation rates with peaks at 24 h and 48 h, respectively (Fig. 3).

Patients were followed-up by physical examination (including change in ischemic ulcers), walking test, control angiography, measurements of ankle-brachial index, acute phase reactant levels at 14 days, 1 month and 2 months after the therapeutic procedure was performed.

All patients showed a marked diminution of the resting pain in the first 2 weeks with consecutive decrease of use of analgesics; this improvement in resting pain was maintained for the following weeks.

Examination of the lower limb showed signs of improved nutrition of the tissues, with increased local temperature and reduction of the area of ulcerative lesions. Both patient number 1 and number 2 presented with

Fig. 2 Changes in C-Reactive Protein value assessed before (baseline) and after (6 h and 2 months) gene therapy

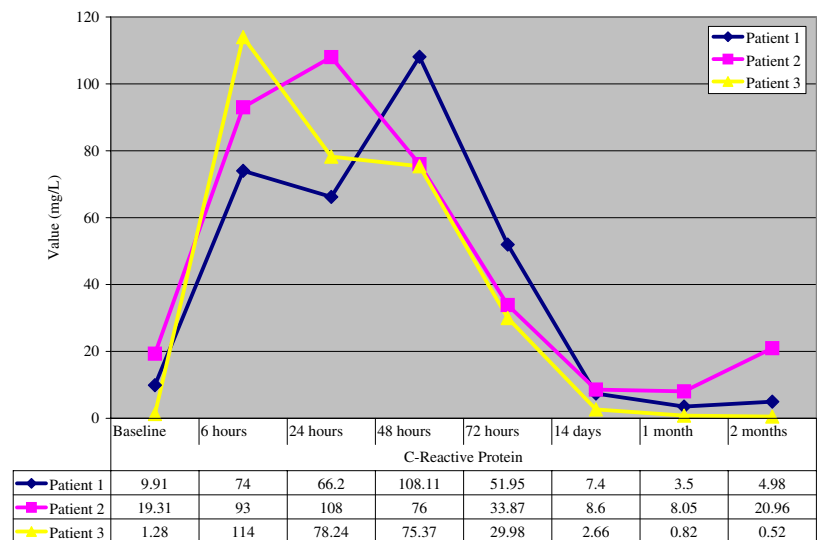
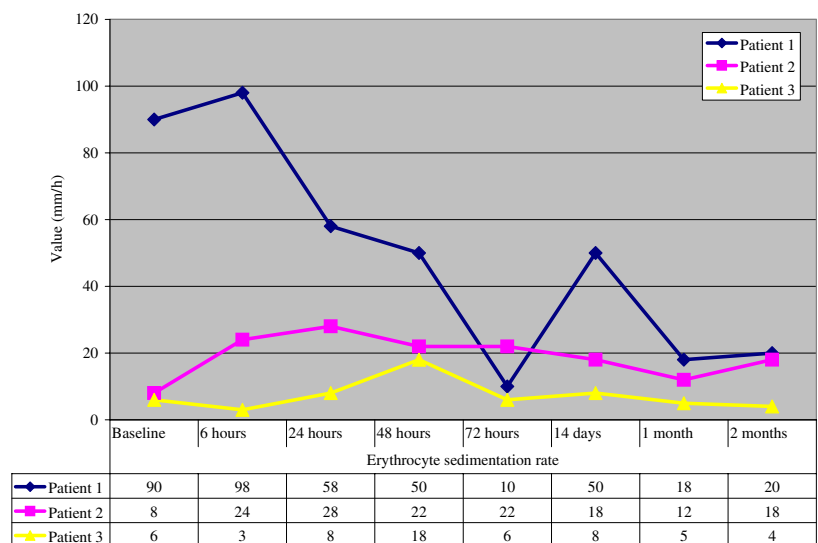


Fig. 3 Changes in erythrocyte sedimentation rate value (mm/h) assessed before (baseline) and after (6 h and 2 months) gene therapy



incipient ischaemic gangrene at the beginning of the study and both showed a significant decrease in the area of gangrene after therapy (see Table 1 and Fig. 4).

All 3 patients showed significant improvement of the performance in the walking test at 2 months after therapeutic intervention (Fig. 5). The ankle-brachial index did not show significant changes in any of the three patients suggesting that the central blood-flow axis in the calf was not significantly modified (data not shown).

Control angiographies at two weeks, one months and 2 months after gene transfer were negative for signs of progression of atherosclerosis or neo-vascularization. In one case (patient number 3 in Table 1) we were able to detect on the angiography performed two months after the procedure a fine, subtle network of new collateral blood vessels at the level of the calf (Fig. 6).

Further assessment of the clinical and angiographic status will be performed at 6 months interval in the future.

Discussion

Patients with chronic severe lower limb ischaemia classified as not suitable for conventional revascularization therapy (so-called ‘‘no-option patients’’) represent 10–15% of all patients with peripheral artery disease and usually receive only conservative management such as pain control and vasodilators (Wolfe 1986; Albers et al. 1992). Both the prognosis and quality of life for these patients are poor. Up to now, no pharmacological therapy has been shown to improve the natural history of severe lower limb ischaemia (Stapanavatr et al. 2004).

Fig. 4 Patient with chronic lower limb ischaemia. Pictures were taken on day 0 (left) and 2 months after *VEGF* gene therapy (right)

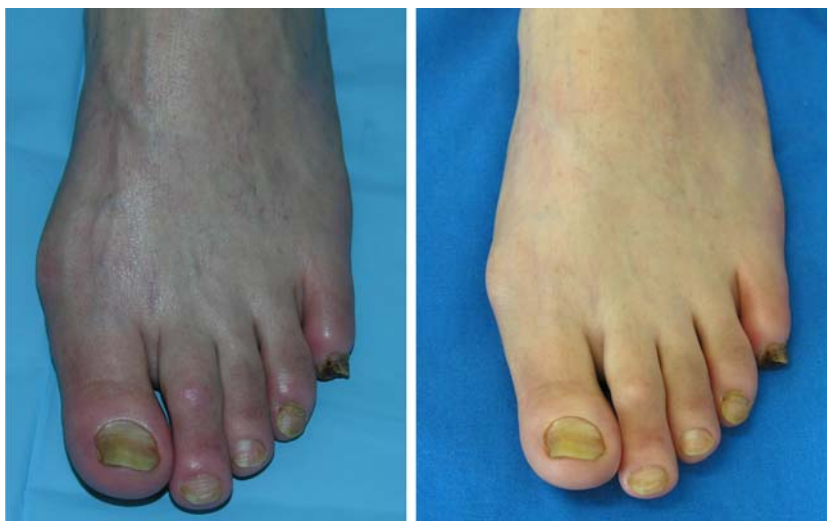

Fig. 5 Chart representing the walking test results for the 3 patients before gene therapy (the first symbol on each coloured line), after 1 month (the second symbol on each coloured line) and 2 months (the third symbol on each coloured line), respectively

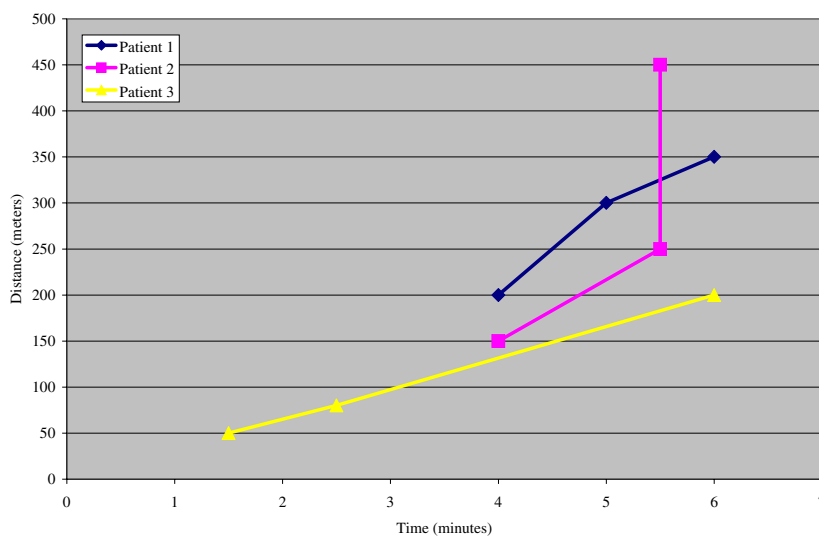
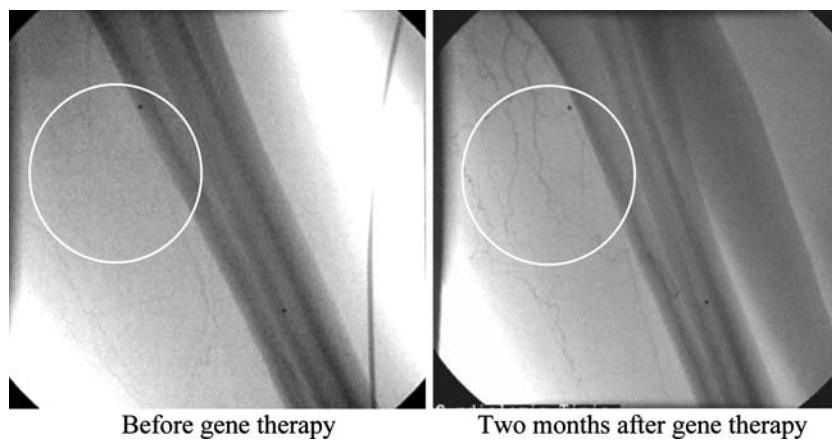

Fig. 6 Angiographic assessment of collateral vessel formation in 1 patient. Compared to the angiography performed before *VEGF* gene therapy, new developed collateral vessels were visible at the calf level two months after plasmid injection (see the encircled area)



Collateral vessels could provide an important blood flow in the case of arterial occlusion. Angiogenic gene therapy aims to increase collateral vessels in ischaemic areas by the

injection of angiogenic factor. Consequently, the limb ischaemia is reduced and the clinical symptoms such as claudication, resting pain, evolution of ischaemic wounds

are improved leading to a better prognosis for these patients. VEGF has been proved as a specific mitogen for endothelial cells (Keck et al. 1989; Leung et al. 1989). Experimental and clinical studies have reported that VEGF could be an alternative treatment for patients with critical limb ischaemia because it induces the formation of new collateral vessel in ischaemic areas (Takeshita et al. 1994; Isner et al. 1996; Isner et al. 1998; Shyu et al. 2003).

Given previous results on animal models, there are concerns over the appearance of abnormal angiogenesis associated with the use of angiogenic growth factors (Bacic et al. 1995; Anghel et al. 2002). Studies in mice have shown that while over-expression of VEGF induces the growth of blood vessels, the capillaries are leaky, the tissues are inflamed and the blood vessels have an abnormal “corkscrew-like” shape. To address this problem in humans VEGF alone should either be delivered over the long-term, at the appropriate dose and time using regulatable vectors, or transiently at low levels (Blau and Banfi 2001). The results of a previous study have reported beneficial clinical effects for patients who received intramuscular administration of *VEGF* gene-carrying plasmid (phVEGF₁₆₅)—this injection was repeated once at 4 weeks, resulting in a total of 4,000 µg phVEGF₁₆₅ (Kusumanto et al. 2006).

Our study on short term effects of angiogenic therapy in severe lower limb ischaemia suggests that muscle *VEGF*₁₆₅ over-expression might constitute a promising therapeutic approach. We find significant that all three subjects showed an improved performance on the walking carpet, which suggests an increase in blood supply of the lower limb muscles. Surprisingly, the presumed improvement in collateral blood flow was substantiated in only one case by a control angiography at two months after the procedure, with the appearance of a network of new collateral blood vessels. We are tempted to attribute the lack of signs of vascular neo-formation in the other two patients to the limitations inherent to this method of investigation. Current methods used to perform diagnostic contrast angiography cannot provide images of arteries measuring <200 µm in diameter (Takeshita et al. 1997). Thus, conventional angiographic techniques used in the present study may have failed to depict the full extent of angiogenesis achieved after gene therapy.

The most obvious result of our VEGF₁₆₅ therapy study is a marked decrease of the pain (both resting pain and claudication, the use of analgics) experienced by all three patients. We have noticed that the decrease of pain was more significant compared to the resolution of gangrene. It is possible that the decrease in ischaemic resting pain was caused not only by increased blood flow but also by recovery from ischaemic neuropathy. It has been demonstrated that over-expression of VEGF results in the resto-

ration of large- and small-fiber peripheral nerve function in diabetic and ischaemic neuropathy models (Schratzberger et al. 2000; Isner et al. 2001; Schratzberger et al. 2001; Simovic et al. 2001; Veves et al. 2001).

We were not able to measure the levels of blood VEGF neither before nor after gene transfer. However, it has been reported that baseline plasma VEGF is highly variable and there is a marginal or no increase after intramuscular transfer of phVEGF₁₆₅ (Freedman et al. 2002).

In conclusion, we describe the clinical evolution of three patients with chronic severe lower limb ischaemia treated with a single dose of intramuscular injection with naked plasmid DNA encoding the 165-amino acid isoform of VEGF. We show that excepting a transient increase of the acute phase reactant levels and an isolated fever episode, the procedure was well tolerated and showed no serious side effects directly related to gene transfer. One study has shown transient lower-extremity oedema in 52% of the patients who received intramuscular gene transfer for critical limb ischaemia. Development of oedema was unrelated to the dose of phVEGF₁₆₅ and the treatment was typically limited to a brief course of oral diuretics (Baumgartner et al. 2000). It is noteworthy in our study that there was no evidence of oedema in patients transfected with the human *VEGF* gene.

We are aware that both the number of patients included in this study and the duration of the follow-up does not allow us to draw definitive conclusions regarding the benefits, drawbacks and safety of such a procedure. Particularly weakening our results is the lack of a control group. This is a direct result of the extremely low number of patients matching the inclusion criteria; a placebo “group” of one patient would have not added a statistical value to our study. None of the patients knew whether the intramuscular injections contained naked VEGF₁₆₅ plasmid DNA or 0.9% NaCl. Given the low number of patients included in our study, we consider that this approach prevented a placebo bias.

Given the failure of previous conventional therapy we are tempted to state that overexpression of VEGF at the level of the thigh and calf muscles prevented the amputation, which would have been the only alternative left for the three patients.

Larger (and with a longer-term follow-up) studies are needed to assess the long term outcome (in terms of efficacy and safety) of *VEGF*-based therapy in patients with severe chronic lower limb ischaemia.

Summary

Gene therapy with vascularization promoting factors (VEGF, angiopoietins, hepatocyte growth factor) has been established as a potential strategy for inducing re-vascularization in patients with severe lower limb ischaemia. The present study evaluates the clinical outcome (rest pain,

claudication, evolution of ischaemic ulcerative lesions, walking distance on rolling carpet as assessed by the Gardner protocol) and angiographically assesses the formation of new blood vessels after VEGF₁₆₅ gene therapy in 3 patients with severe chronic lower limb ischaemia, showing that intramuscular VEGF gene transfer represents a promising therapeutic approach for patients who do not respond to conventional therapy.

Acknowledgements We are grateful to Ioan Ovidiu Sirbu MD, PhD for reading this manuscript and making critical suggestions. This work was supported by the Romanian Ministry of Education and Research through a grant from the Academy of Medical Sciences—VIASAN Programme.

References

- Albers M, Fratezi AC, DeLuccia N (1992) Assessment of quality of life of patients with severe ischaemia as a result of infrainguinal arterial occlusive disease. *J Vasc Surg* 16:54–59
- Anghel A, Sirbu IO, Marian C, Tamas L, Motoc M (2002) Introduction to gene therapy; Mirton Publishing House, Timisoara, Romania
- Bacic M, Edwards NA, Merrill MJ (1995) Differential expression of vascular endothelial growth factor (vascular permeability factor) forms in rat tissues—Short Communication. *Growth Factors* 12:11–15
- Baumgartner I, Rauh G, Pieczek A, Wuensch D, Magner M, Kearney M, Schainfeld R, Isner JM (2000) Lower-extremity edema associated with gene transfer of naked DNA encoding vascular endothelial growth factor. *Ann Intern Med* 132(11):880–884
- Blau MH, Banfi A (2001) The well-tempered vessel. *Nat Med* 7:532–534
- Brown AL, Juergens JL (1972) Arteriosclerosis and atherosclerosis. In: Allen EV et al (eds) *Peripheral vascular disease*. Saunders, Philadelphia, pp 57–66
- Dantz D, Bewersdorf J, Fruehwald-Schultes B, Kern W, Jelkmann W, Born J, Fehm HL, Peters A (2002) Vascular endothelial growth factor: a novel endocrine defensive response to hypoglycemia. *J Clin Endocr Metab* 87:835–840
- Eskelinen E, Lepantalo M, Hietala EM, Sell H, Kauppila L, Maenpaa I, Pitkanen J, Salminen-Peltola P, Leutola S, Eskelinen A, Kivioja A, Tukiainen E, Lukinmaa A, Brasken P, Railo M (2004) Lower limb amputations in Southern Finland in 2000 and trends up to 2001. *Eur J Vasc Endovasc Surg* 27:193–200
- Freedman SB, Vale P, Kalka C, Kearney M, Pieczek A, Symes J, Losordo D, Isner JM (2002) Plasma vascular endothelial growth factor (VEGF) levels after intramuscular and intramyocardial gene transfer of VEGF-1 plasmid DNA. *Hum Gene Ther* 13:1595–1603
- Gerritsen ME (2005) HGF and VEGF: a dynamic duo. *Circ Res* 96:272–273
- Gordon T, Kannel WB (1972) Predisposition to atherosclerosis in the head, heart, and legs. The Framingham study. *JAMA* 221:661–666
- Helmlinger G, Endo M, Ferrara N, Hlatky L, Jain RK (2000) Formation of endothelial cell networks. *Nature* 405:139–141
- Isner JM, Baumgartner I, Rauh G, Schainfeld R, Blair R, Manor O, Razvi S, Symes JF (1998) Treatment of thromboangiitis obliterans (Buerger's disease) by intramuscular gene transfer of vascular endothelial growth factor: preliminary clinical results. *J Vasc Surg* 28:964–973
- Isner JM, Pieczek A, Schainfeld R, Blair R, Haley L, Asahara T, Rosenfield K, Razvi S, Walsh K, Symes JF (1996) Clinical evidence of angiogenesis after arterial gene transfer of phVEGF₁₆₅ in patient with ischaemic limb. *Lancet* 348:370–374
- Isner JM, Ropper A, Hirst K (2001) VEGF gene transfer for diabetic neuropathy. *Hum Gene Ther* 12:1593–1594
- Keck PJ, Hauser SD, Krivi G, Sanzo K, Warren T, Feder J, Connolly DT (1989) Vascular permeability factor, an endothelial cell mitogen related to PDGF. *Science* 246:1309–1312
- Kusumanto YH, Van Weel V, Mulder NH, Smit AJ, Van Den Dungen JJAM, Hooymans JMM, Sluiter WJ, Tio RA, Quax PHA, Gans ROB, Dullaart RPF, Hospers GAP (2006) Treatment with intramuscular vascular endothelial growth factor gene compared with placebo for patients with diabetes mellitus and critical limb ischemia: a double blind randomized trial. *Hum Gene Ther* 17:683–691
- Leung DW, Cachianes G, Kuang WJ, Goeddel DV, Ferrara N (1989) Vascular endothelial growth factor is a secreted angiogenic mitogen. *Science* 246:1306–1309
- Poltorak Z, Cohen T, Sivan R, Kandelis Y, Spira G, Vlodaysky I, Keshet E, Neufeld G (1997) VEGF₁₄₅, a secreted vascular endothelial growth factor isoform that binds to extracellular matrix. *J Biol Chem* 272:7151–7158
- Rajagopalan S, Shah M, Luciano A, Crystal R, Nabel EG (2001) Adenovirus-mediated gene transfer of VEGF₁₂₁ improves lower-extremity endothelial function and flow reserve. *Circulation* 104:753–755
- Schratzberger P, Schratzberger G, Silver M, Curry C, Kearney M, Magner M, Alroy J, Adelman LS, Weinberg DH, Ropper AH, Isner JM (2000) Favorable effect of VEGF gene transfer on ischemic peripheral neuropathy. *Nat Med* 6:405–413
- Schratzberger P, Walter DH, Rittig K, Bahlmann FH, Pola R, Curry C, Silver M, Krainin JG, Weinberg DH, Ropper AH, Isner JM (2001) Reversal of experimental diabetic neuropathy by VEGF gene transfer. *J Clin Invest* 107:1083–1092
- Shyu KG, Chang H, Wang BW, Kuan P (2003) Intramuscular vascular endothelial growth factor gene therapy in patients with chronic critical leg ischaemia. *Am J Med* 114:85–92
- Simovic D, Isner JM, Ropper AH, Pieczek A, Weinberg DH (2001) Improvement in chronic ischemic neuropathy after intramuscular phVEGF₁₆₅ gene transfer in patients with critical limb ischaemia. *Arch Neurol* 58:761–768
- Soker S, Takashima S, Miao HQ, Neufeld G, Klagsbrun M (1998) Neuropilin-1 is expressed by endothelial and tumor cells as an isoform-specific receptor for vascular endothelial growth factor. *Cell* 92:735–745
- Stapanavatr W, Ungkittapaiboon W, Karnjanabatr B (2004) Conservative regimen for chronic critical limb ischemia. *J Med Assoc Thai* 87(3):310–318
- Takeshita S, Isshiki T, Tanaka E, Eto K, Miyazawa Y, Tanaka A, Shinozaki Y, Hyodo K, Ando M, Kubota M, Tanioka K, Umetani K, Ochiai M, Sato T, Mori H, Miyashita H (1997) Use of synchrotron radiation microangiography to assess development of small collateral arteries in a rat model of hindlimb ischaemia. *Circulation* 95:805–808
- Takeshita S, Pu LQ, Stein LA, Sniderman AD, Bunting S, Ferrara N, Isner JM, Symes JF (1994) Intramuscular administration of vascular endothelial growth factor induces dose-dependent collateral artery augmentation in a rabbit model of persistent limb ischaemia. *Circulation* 90(5pt2):II228–II234
- Thurston G, Rudge JS, Ioffe E, Zhou H, Ross L, Croll SD, Glazer N, Holash J, McDonald DM, Yancopoulos GD (2000) Angiopoietin-1 protects the adult vasculature against plasma leakage. *Nat Med* 6:460–463

- Thurston G, Suri C, Smith K, McClain J, Sato TN, Yancopoulos GD, McDonald DM (1999) Leakage-resistant blood vessels in mice transgenically overexpressing angiopoietin-1. *Science* 286:2511–2514
- Tischer E, Mitchell R, Hartman T, Silva M, Gospodarowicz D, Fiddes JC, Abraham JA (1991) The human gene for vascular endothelial growth factor: multiple protein forms are encoded through alternative exon splicing. *J Biol Chem* 266:11947–11954
- Veves A, King GL (2001) Can VEGF reverse diabetic neuropathy in human subjects? *J Clin Invest* 107:1215–1218
- Wolfe JHN (1986) Defining the outcome of critical ischaemia: a one year prospective study. *Br J Surg* 73:321–328